

Case Report

Open Access



Wolfring dacryops: a case of acquired ptosis in a child

Sammie E. Fung¹, Clara J. Men², Bobby S. Korn^{2,3}, Don O. Kikkawa^{2,3}, Catherine Y. Liu²

¹University of California San Diego School of Medicine, La Jolla, CA 92037, USA.

²Division of Oculofacial Plastic and Reconstructive Surgery, UC San Diego Department of Ophthalmology, La Jolla, CA 92037, USA.

³Division of Plastic Surgery, UC San Diego Department of Surgery, La Jolla, CA 92037, USA.

Correspondence to: Dr. Catherine Y. Liu, Division of Oculofacial Plastic and Reconstructive Surgery, UC San Diego Department of Ophthalmology, La Jolla, CA 92037, USA. E-mail: yul107@health.ucsd.edu

How to cite this article: Fung SE, Men CJ, Korn BS, Kikkawa DO, Liu CY. Wolfring dacryops: a case of acquired ptosis in a child. *Plast Aesthet Res* 2020;7:55. <http://dx.doi.org/10.20517/2347-9264.2020.60>

Received: 31 Mar 2020 **First Decision:** 2 Sep 2020 **Revised:** 9 Sep 2020 **Accepted:** 29 Sep 2020 **Published:** 21 Oct 2020

Academic Editor: Raúl González-García **Copy Editor:** Cai-Hong Wang **Production Editor:** Jing Yu

Abstract

A healthy, nine-year-old boy presented to the oculofacial plastic service with left upper eyelid ptosis progressively worsening for the past two years. On eyelid eversion, a cystic mass was found on the medial palpebral conjunctiva. Magnetic resonance imaging confirmed a fluid-filled cystic structure without posterior orbital extension. Based on imaging and clinical findings, the patient was diagnosed with dacryops of the accessory lacrimal duct of the Wolfring gland. Although prior literature suggests that the risk of Wolfring dacryops may be associated with conjunctival scarring, this report presents a case of spontaneous Wolfring dacryops without history of ocular manipulation or inflammation. Small, asymptomatic cases of dacryops can be safely monitored with serial eye exams.

Keywords: Accessory gland, ductal cyst, lacrimal gland, Wolfring gland, dacryops

INTRODUCTION

Blepharoptosis (or ptosis) is a common presenting complaint in the oculoplastics clinic and can be found amongst all age groups. In the adult population, acquired aponeurotic ptosis is the most common type, making up about 60% of cases in one study^[1]. In children, congenital ptosis, a type of myogenic ptosis,



© The Author(s) 2020. **Open Access** This article is licensed under a Creative Commons Attribution 4.0 International License (<https://creativecommons.org/licenses/by/4.0/>), which permits unrestricted use, sharing, adaptation, distribution and reproduction in any medium or format, for any purpose, even commercially, as long as you give appropriate credit to the original author(s) and the source, provide a link to the Creative Commons license, and indicate if changes were made.



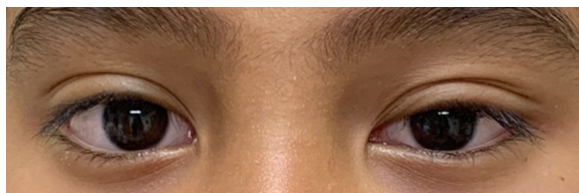

Figure 1. External front view of the patient, who presents with ptosis of the left upper eyelid

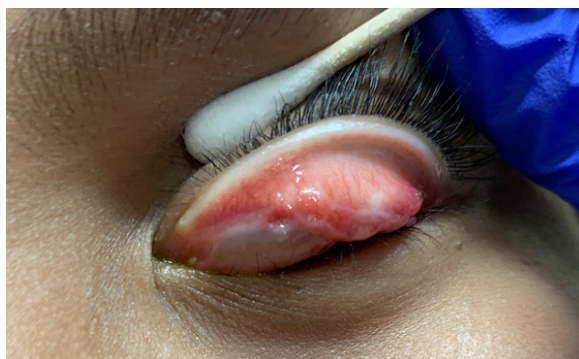

Figure 2. Eversion of the left upper eyelid revealed a bluish cystic mass

represents the majority of cases, making up about 79%-90% of pediatric cases^[2-4]. Pediatric ptosis associated with amblyopia, refractive error, and strabismus warrants surgery^[5,6].

Acquired childhood ptosis is less common, making up the remainder of pediatric cases (10%-21%)^[2,3]. Mechanical ptosis may result from masses, such as neurofibroma, capillary hemangioma, infiltration, inflammation, and foreign body, and may represent up to 2% of all pediatric cases^[3]. Dacryops are cysts arising from the lacrimal ductules and can rarely present as an acquired mechanical ptosis^[7]. Here, we report a patient with newly acquired mechanical ptosis due to a Wolfring dacryops (WD) with no known history of neurological, myogenic, or congenital deficits.

CASE REPORT

A healthy nine-year old Asian male presented with new onset left upper eyelid ptosis and swelling gradually worsening over the last two years [Figure 1]. He denied pain, vision loss, diplopia, or discharge. He had no previous history of trauma, periocular inflammation, or prior surgeries.

On exam, his vision was 20/20 corrected OU. He had a margin reflex distance (MRD1) of 4.5 mm OD, 2 mm OS, a margin fold distance of 3 mm OD, 4.5 mm OS, a levator function of 15 mm OD and 13 mm OS, and no lagophthalmos. He had no proptosis or globe dystopia. Extraocular motility was full OU. There was no relative afferent pupillary defect. On palpation, there was a soft, non-tender, mobile mass of the medial left upper eyelid. Eversion of the upper lid revealed a cystic mass with a bluish hue [Figure 2]. The remainder of his exam was unremarkable.

To better characterize the mass, magnetic resonance imaging (MRI) with and without gadolinium enhancement was performed, which revealed an ovoid-shaped cystic lesion located in the left medial upper eyelid, measuring 10 mm × 7 mm × 8 mm [Figure 3]. The cyst was confined to the eyelid without posterior, orbital extension. The diagnosis of a ductal cyst of the accessory lacrimal gland (i.e., Wolfring dacryops) was made. Surgical excision was discussed but the patient and family opted to observe given the benign nature of the lesion.

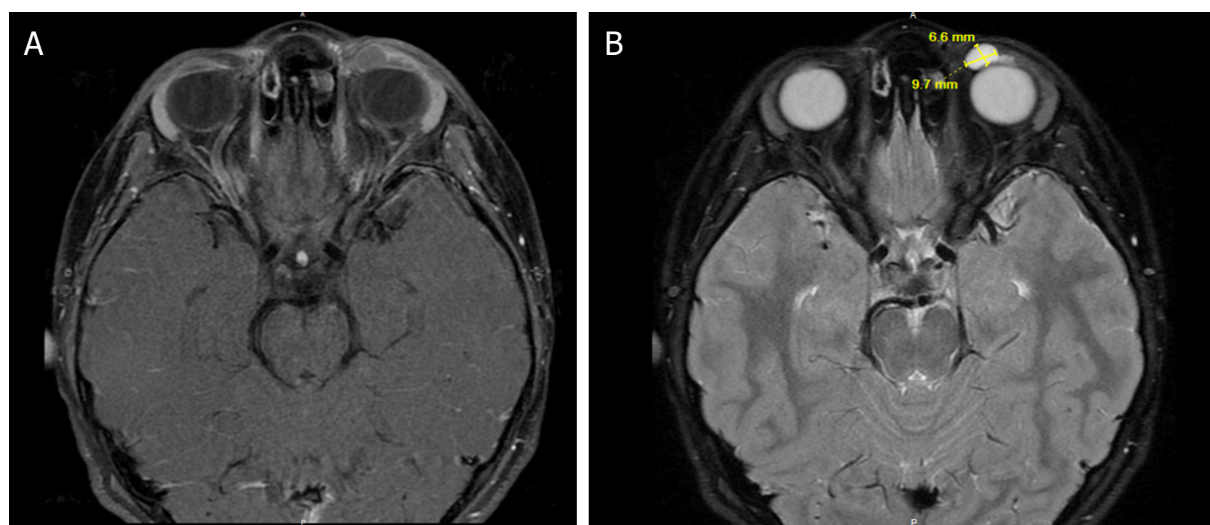


Figure 3. Magnetic resonance imaging scan (axial view) reveals a T1 hypointense (A) and T2 hyperintense (B) fluid filled cystic structure in the left upper eyelid consistent with Wolfring dacryops

Table 1. Summary table of previously reported cases of dacryops of the accessory lacrimal gland^[8,10,11,15-22]

Unilateral	48 out of 49 (98%)
Bilateral	1 out of 49 (2%)
Upper eyelid	35 out of 49 (71%)
Lower eyelid	14 out of 49 (29%)

DISCUSSION

Dacryops is a closed ductal cyst arising from lacrimal gland tissue. It presents as a painless, well-circumscribed, translucent lesion often with a bluish tint, and it may be derived from the main or accessory lacrimal glands^[8]. These cysts are commonly classified by their location, with palpebral lobe cysts of the main lacrimal gland (simple dacryops) being the most common and cysts of the accessory lacrimal glands of Krause and Wolfring being quite rare^[9-11]. However, there are limited data on its incidence and prevalence. The majority of cases have been reported from Saudi Arabia, where the prevalence of cysts of the accessory lacrimal glands has been found to be between 1 in 6,800^[10] and 1 in 7000^[11]. The estimates in these reports are based on studies of patients seen in an oculoplastic clinic and may overestimate the prevalence of these lesions due to ascertainment bias.

Dacryops usually occur unilaterally^[12,13], but they have rarely been shown to occur bilaterally^[14,15]. The upper eyelid is more commonly involved (70.8%) than the lower eyelid, likely due to the fact that there are more ducts in the upper eyelid^[8]. In previously reported cases of dacryops of the accessory glands, the mean age of occurrence was 30.5 years (ranging from ages 2 to 81), without male/female predominance^[8,10,11,15-22] [Table 1].

The etiology of WD is unclear, and it has been hypothesized that conjunctival scarring (from previous trauma, infection, or chronic inflammation) or IgA hypersecretion may contribute to its formation^[10-12,21]. A review of the literature by Galindo-Ferreiro estimates that up to 85% of dacryops have been linked to previous conjunctival scarring^[11]. In our patient's case, no predisposing cause was identified.

While congenital ptosis in children is more common, acquired ptosis is rare^[2,23] and warrants a more detailed exam and history. Eversion of the eyelid made the clinical diagnosis of WD in this case, based on the mobile, non-tender mass located near the superior tarsal border. MRI findings can be supportive and

typically show a T2 hyperintense, T1 hypointense mass with enhancement of the wall after gadolinium consistent with a fluid filled cyst^[8,24]. Histopathology of WD typically reveals a non-keratinizing, double layer of cuboidal to columnar epithelium^[9,11,12,21]. Given the location of the cyst at the superior tarsal border, the cyst could potentially stretch or cause a dehiscence of the Muller's muscle underneath, which is a potential alternative mechanism for the ptosis^[25].

Complete surgical excision of the intact cysts is recommended for symptomatic lesions (large lesions, lesions that induce significant refractive error, symptomatic ptosis, disfigurement, or are potentially amblyogenic)^[11,13,26], but our patient's upper eyelid WD was asymptomatic, and his mild ptosis was not amblyogenic. However, ptosis in children can often cause amblyopia, and, as such, a referral to an ophthalmologist may be warranted. Dacryops is a benign entity, but complicated cases involving fistulization of the cyst, hemorrhage, and superimposed infection have been reported^[9]. After a discussion of options, the patient and his family decided to monitor the lesion with serial eye exams.

This report describes a rare cause of mechanical ptosis in a child and illustrates the importance of a thorough eye exam in cases of acquired ptosis in childhood.

DECLARATIONS

Acknowledgments

The authors thank Research to Prevent Blindness (RPB) for their support of the UC San Diego Shiley Eye Center.

Authors' contributions

Made substantial contributions to the conception and design of this case, contributed to the drafting and editing of the manuscript, and approved the final version to be published: Fung SE, Liu CY

Made substantial contributions to the drafting and editing of the manuscript, and approved the final version to be published: Men CJ, Korn BS, Kikkawa DO

Availability of data and materials

Not applicable.

Financial support and sponsorship

None.

Conflict of interest

All authors declared that there are no conflicts of interest.

Ethical approval and consent to participate

The case report adheres to the ethical principles outlined in the Declaration of Helsinki and is HIPAA compliant. The patient consented to participation of the clinic visit and consultation in accordance with the institution policy.

Consent for publication

Consent was obtained from the patient for publication of images and details of the clinical case discussed.

Copyright

© The Author(s) 2020.

REFERENCES

1. Lim JM, Hou JH, Singa RM, Aakalu VK, Setabutr P. Relative incidence of blepharoptosis subtypes in an oculoplastics practice at a tertiary care center. *Orbit* 2013;32:231-4.
2. Griepentrog GJ, Diehl NN, Mohney BG. Incidence and demographics of childhood ptosis. *Ophthalmology* 2011;118:1180-3.
3. Lee V, Konrad H, Bunce C, Nelson C, Collin JR. Aetiology and surgical treatment of childhood blepharoptosis. *Br J Ophthalmol* 2002;86:1282-6.
4. Harrad RA, Graham CM, Collin JR. Amblyopia and strabismus in congenital ptosis. *Eye (Lond)* 1988;2:625-7.
5. Gillum WN, Anderson RL. Dominantly inherited blepharoptosis, high myopia, and ectopia lentis. *Arch Ophthalmol* 1982;100:282-4.
6. Oral Y, Ozgur OR, Akcay L, Ozbas M, Dogan OK. Congenital ptosis and amblyopia. *J Pediatr Ophthalmol Strabismus* 2010;47:101-4.
7. Salam A, Barrett AW, Malhotra R, Olver J. Marsupialization for lacrimal ductular cysts (dacryops): a case series. *Ophthalmic Plast Reconstr Surg* 2012;28:57-62.
8. Alsulaiman HM, Fatani DR, Al Sheikh O, Elkhamary S, Maktabi A, et al. Krause's accessory lacrimal gland dacryops - case report and literature review. *Orbit* 2020;1-5.
9. Bullock JD, Fleishman JA, Rosset JS. Lacrimal ductal cysts. *Ophthalmology* 1986;93:1355-60.
10. Weatherhead RG. Wolfring Dacryops. *Ophthalmology* 1992;99:1575-81.
11. Galindo-Ferreiro A, Alkatan HM, Muinos-Diaz Y, Akaishi PM, Galvez-Ruiz A, et al. Accessory lacrimal gland duct cyst: 23 years of experience in the Saudi population. *Ann Saudi Med* 2015;35:394-9.
12. Tanaboonyawat S, Idowu OO, Copperman TS, Vagefi MR, Kersten RC. Dacryops - a review. *Orbit* 2020;39:128-34.
13. Ozgonul C, Uysal Y, Ayyildiz O, Kucukevcilioglu M. Clinical features and management of dacryops. *Orbit* 2018;37:262-5.
14. Tsiouris AJ, Deshmukh M, Sanelli PC, Brazzo BG. Bilateral dacryops: correlation of clinical, radiologic, and histopathologic features. *AJR Am J Roentgenol* 2005;184:321-3.
15. Feijó ED, Alencastro Landim G, de Melo Dias M, Alves de Souza BA, Murillo Limongi R, et al. Giant bilateral cysts of the accessory lacrimal glands of Wolfring in a child. *Ophthalmic Plast Reconstr Surg* 2020;36:e4-6.
16. Durán JA, Cuevas J. Cyst of accessory lacrimal gland. *Br J Ophthalmol* 1983;67:485-6.
17. Remulla HD, Rubin PA. Giant dacryops in a patient with ocular cicatricial pemphigoid. *Br J Ophthalmol* 1995;79:1052-3.
18. Woo KI, Kim YD. Cyst of accessory lacrimal gland. *Korean J Ophthalmol* 1995;9:117-21.
19. O'Duffy D, Watts P. Wolfring dacryops and needling. *Acta Ophthalmol Scand* 1997;75:319.
20. Jastrzebski A, Brownstein S, Jordan DR, de Nanassy J. Dacryops of Krause gland in the inferior fornix in a child. *Arch Ophthalmol* 2012;130:252-4.
21. Lam K, Brownstein S, Jordan DR, Jastrzebski A. Dacryops: a series of 5 cases and a proposed pathogenesis. *JAMA Ophthalmol* 2013;131:929-32.
22. Khoury NJ, Haddad MC, Tawil AN, Ma'luf RN. Ductal cysts of the accessory lacrimal glands: CT findings. *Am J Neuroradiol* 1999;20:1140-2.
23. Rasiah S, Hardy TG, Elder JE, Ng CY, McNab A. Etiology of pediatric acquired blepharoptosis. *J AAPOS* 2017;21:485-7.
24. Jakobiec FA, Zakka FR, Perry LP. The cytologic composition of dacryops: an immunohistochemical investigation of 15 lesions compared to the normal lacrimal gland. *Am J Ophthalmol* 2013;155:380-96.e1.
25. Nakauchi K, Katori N, Imagawa Y, Yamada T. A case report on lacrimal ductal cyst causing unilateral blepharoptosis. *Br J Ophthalmol* 2009;93:1143-5.
26. Men CJ, Yang P, Gur Z, Paik JS, Kikkawa DO, et al. Complete excision of a simple dacryops using fibrin sealant and trypan blue mixture. *Ophthalmic Plast Reconstr Surg* 2019;35:e16-8.