

Original Article

Open Access



Free tissue transfer for lower extremity trauma in the pediatric patient

Sammy Othman, Denis Knobel

Division of Plastic and Reconstructive Surgery, Department of Surgery, Northwell Health, New York, NY 11021, USA.

Correspondence to: Dr. Sammy Othman, Division of Plastic and Reconstructive Surgery, Department of Surgery, Northwell Health, 600 Northern Blvd, Great Neck, New York, NY 11021, USA. E-mail: Sothman@northwell.edu; sothman13@gmail.com

How to cite this article: Othman S, Knobel D. Free tissue transfer for lower extremity trauma in the pediatric patient. *Plast Aesthet Res* 2022;9:21. <https://dx.doi.org/10.20517/2347-9264.2022.03>

Received: 13 Jan 2022 **First Decision:** 24 Jan 2022 **Revised:** 26 Jan 2021 **Accepted:** 11 Feb 2022 **Published:** 18 Mar 2022

Academic Editor: Matthew L Iorio **Copy Editor:** Jia-Xin Zhang **Production Editor:** Jia-Xin Zhang

Abstract

Aim: The utilization of free-tissue transfer secondary to traumatic lower extremity defects in the pediatric population is scarcely described. Factors include microsurgeon inexperience, inadequate center resources, and fear of historically described poor surgical outcomes. The aim of this study is to investigate more recent articles describing free-flap microsurgical reconstruction for these defects.

Methods: A systematic review of the literature was conducted through the online databases PubMed, Embase, and Web of Science, examining for articles with at least 20 subjects utilizing free-tissue transfer for soft-tissue defects of the pediatric (aged 18 and younger) lower extremity following traumatic etiology since 2005. Outcomes included flap failure, return to the operating room, and functional status, where available.

Results: Seven studies were deemed appropriate for inclusion, with a total of 243 flaps included. Motor vehicle and motorcycle accidents were greater than 75% of total etiology. Most defects involved the foot or ankle (65.1%). In total, perforator flaps compromised the majority of flaps (54%), with the most common being the anterolateral thigh, the scapular/parascapular, and deep inferior epigastric flaps. Less common perforators included the groin flap, tensor fascia lata, radial forearm, lateral arm, and thoracodorsal perforator flap. Muscle-based flaps were less common (46%), with the latissimus dorsi and rectus muscle flaps composing the majority. The most commonly used recipient vessel was the anterior tibialis (49.5%) and posterior tibialis vessels (45.3%). Most studies performed reconstruction within 7-10 days of presentation. There was a cumulative 6.5% flap failure rate.



© The Author(s) 2022. **Open Access** This article is licensed under a Creative Commons Attribution 4.0 International License (<https://creativecommons.org/licenses/by/4.0/>), which permits unrestricted use, sharing, adaptation, distribution and reproduction in any medium or format, for any purpose, even commercially, as long as you give appropriate credit to the original author(s) and the source, provide a link to the Creative Commons license, and indicate if changes were made.



Conclusion: Free tissue transfer for pediatric lower extremity trauma is an important tool that likely leads to powerful outcomes. Recent trends indicate increasing usage of perforator flaps. This study shows that based on existing data, free flap utilization for pediatric patients is an adequate modality for repair, and may warrant greater consideration moving forward.

Keywords: Reconstructive surgery, pediatric trauma, pediatric lower extremity, microsurgery, soft-tissue, free-tissue transfer

INTRODUCTION

The burden of trauma to the lower extremity presents multi-faceted obstacles to patients, including psychological trauma, functional deficits, and increased health costs^[1,2]. For the surgeon, lower extremity trauma has long presented difficult challenges to achieve adequate reconstruction, and the success of this reconstruction, including vascular, bone, and soft-tissue elements, is heavily correlated with successful limb salvage. Although research has shown that some patients benefit from amputation over limb salvage, the correct decision centers upon a patient-centric approach and involves heavy counseling that necessitates case by case analysis^[1,3-5]. This is magnified in the pediatric population, which presents increased considerations, including long-term sequelae, compared to their adult counterparts^[6-9].

A multi-disciplinary collaborative approach between trauma surgeons, vascular surgeons, orthopedic surgeons, and plastic surgeons is optimal in order to achieve the best possible outcomes. Unfortunately, the literature is limited regarding objective guidelines for appropriate treatment algorithms, as most current reports detail individual-institution experiences^[3,7,10-12]. This is especially highlighted when examining the pediatric population, as this unique cohort of patients presents its own set of questions that many surgeons do not have great experience with nor do not feel as comfortable managing. From a vascular perspective, the revascularization of small vessels may be limited due to either vessel size or out of scope of practice for experienced vascular surgeons^[6-11]. Similarly, the microsurgeon may also have difficulty with the vessel caliber when free tissue transfer is necessary, as well as challenges with appropriate flap selection.

Given the unique cohort of patients that present in the pediatric setting, the aim of this article was to succinctly describe existing treatment patterns for free tissue transfer used to manage pediatric lower extremity trauma. We hypothesize that a heterogenous approach is taken across centers and surgeons who manage these defects, given the relatively small incidence of pediatric lower extremity trauma that requires comprehensive soft-tissue management.

METHODS

A full literature review was conducted using the databases PubMed, Web of Science, and Embase. With the assistance of a medical librarian, a search string strategy was devised using the following terms and synonymous variations in phrasing and spelling: Lower-extremity OR lower-limb OR leg OR ankle OR foot AND trauma AND pediatric OR pediatric AND free flap OR free tissue transfer.

Inclusion criteria encompassed articles describing soft-tissue free-tissue transfer reconstruction of the lower extremity secondary to trauma of pediatric patients (aged 18 or younger) of articles published within the last 15 years (2005-2020). Only articles with at least 20 patients who suffered from traumatic etiology were included. Relevant articles were also extracted from citations on article reviews wherever applicable. There was no minimum mean/median follow-up time. Only articles written in the English language or with an available English translation were considered. All case-series and retrospective studies were included.

Extracted outcomes included flap failure, re-operative rates, and serious infection, defined as those requiring intravenous antibiotics and/or operative debridement.

Articles were excluded if they only discussed anatomical regions aside from the lower-extremity or if there were etiologies other than trauma in which specific details could not be extracted. Articles were also excluded if they used a method of reconstruction of other soft-tissue free flaps. If articles described a mixture of lower-extremity and non-lower extremity reconstruction, but specific results of the lower-extremity reconstruction could not be described, they were excluded. Further, editorials, abstracts, review articles, and technique articles were excluded.

RESULTS

Following the initial search, 313 articles were identified. Screening at the abstract level provided 27 articles for full-text review. After final full-length article review, a total of 7 articles were deemed appropriate for inclusion [Figure 1].

Six of seven studies included were published after 2012, with one being published in 2005. The greatest number of flaps included in a study was 53, with the lowest being 23. Patients were from 2 to 17 years old throughout the studies. Anatomic location was heterogenous, with greater than 60% of subjects focusing solely on foot and ankle defects, while the others were mixed. Traumatic etiology varied largely between studies, with a diverse mix included. Motor vehicle, motorcycle, and pedestrian *vs.* motor vehicle accidents were the most common etiologies for traumatic defects, comprising greater than 75% of total etiology. Also included were alternative-terrain vehicles, gunshot wounds, lawn mower accidents, and falls. Lawn mower accidents were only responsible for foot/ankle defects, while all other etiologies comprised defects at various levels [Table 1]^[12-18].

When available, defect sizes ranged within studies, with most being under 120 cm². However, one study had defect sizes as large as 600 cm². Timing of reconstruction varied, though the majority of studies performed the free flap procedure within 7-10 days after the index presentation of injury. When examining the choice of flap selection, the latissimus dorsi was the most commonly used flap (37.4%), with the anterolateral thigh being the second most common (25.5%). The next most common was the scapular/parascapular (15.6%) and deep inferior epigastric flaps (10.1%). Other utilized flaps included the rectus abdominis (3.3%) serratus (1.6%), gracilis (5.3%), groin flap (2.4%), tensor fascia lata, deltoid, radial forearm, lateral arm, and thoracodorsal perforator flap (all: 0.4%). In total, fascial flaps compromised the majority of flaps (54%) compared to muscle-based flaps (46%). The most commonly used recipient vessel was the anterior tibialis (49.5%) and posterior tibialis vessels (45.3%). The peroneal artery and dorsalis pedis are less described [Table 2].

Most studies reported strong flap outcomes. In total, there was a 6.5% flap failure rate. Return to the operating room was more common, required in 8.7% of cases, while serious infection (requiring prolonged intravenous antibiotics and/or operative debridement) was present in 5.8% of cases. Unfortunately, follow-up time was rarely reported in these studies [Table 3].

DISCUSSION

Lower extremity trauma presents unique challenges often requiring a multi-disciplinary approach from trauma surgeons, orthopedic surgeons, vascular surgeons, plastic surgeons, and often experts from other fields depending upon exact etiology, the extent of bony and soft-tissue loss, and presentation patterns^[19]. Due to limited soft-tissue mobility in young children, local pedicled flaps can often be limited in ability to

Table 1. Study characteristics, patient demographics, and injury mechanism

Author	Year	Number	Age (y)	Leg	Ankle	Foot	ATV	Motorcycle	Car	Gunshot	Pedestrian v. MV	Lawn Mower	Fall
Elbataway et al. ^[15]	2020	34	3-16	0	3	31	0	0	21	0	0	7	6
Rinker et al. ^[12]	2005	26	2-17	0	26 foot/ankle		6	4	2	4	3	4	3
Lee et al. ^[13]	2020	53	11-17	37	0	0	0	5	6	9	15	0	4
Momeniet al. ^[14]	2016	40	1-17	14	9	17	0	0	0	0	0	0	0
Hu et al. ^[16]	2015	25	4-14	0	5	20	0	19	3	0	0	0	0
Sui et al. ^[17]	2019	42	2-13	9	11	22	N/A						
Khadim et al. ^[18]	2019	23	5-16	23	4	3	0	0	30	0	0	0	0

ATV: All-terrain vehicle; MV: Motor vehicle.

Table 2. Flap and recipient vessel selection

Author	Defect Size (cm ²)	Timing (d)	ALT	Scapular/ Parascapular	LD	RA	DIEP	Serratus	Gracilis	Groin	TDP	TFL	Deltoid	RFF	LA	AT	PT	DP	Peroneal
Elbataway et al. ^[15]	50-92	N/A	5	0	29	0	0	0	0	0	0	0	0	0	0	27	5	2	0
Rinker et al. ^[12]	N/A	8	0	0	15	4	0	4	3	0	0	0	0	0	0	N/A			
Lee et al. ^[13]	30-600	< 7 d (68.8%) 7-90 d (42.1%) > 90 d (35.7%)	5	0	28	7	0	0	4	4	1	1	1	0	0	18	28	2	3
Momeniet al. ^[14]	N/A	N/A	16	1	19	1	0	0	3	0	0	0	0	1	1	8	27	2	1
Hu et al. ^[16]	117	8.7	25	0	0	0	0	0	0	0	0	0	0	0	0	17	8	0	0
Sui et al. ^[17]	24-72	N/A	0	21	0	0	21	0		0	0	0	0	0	0	24	18	0	0
Khadim et al. ^[18]	N/A	2	11	16	0	0	0	0	3	2	0	0	0	0	0	N/A			

cm: Centimeters; d: days; ALT: anterolateral thigh flap; LD: latissimus dorsi; RA: rectus Abdominis; TDP: thoracodorsal perforator; TFL: tensor fascia lata; RFF: radial forearm; LA: lateral arm; AT: anterior tibial artery; PT: posterior tibial artery; DP: dorsalis pedis artery.

address defect size. Cross-leg flaps have been documented to help address this but require prolonged immobilization and re-operation, both of which are unfavorable in the pediatric population^[20,21]. For these reasons, it may often be necessary to pursue alternate means of coverage. The use of free-tissue transfer in the adult population is well documented, though the pediatric population is less described given hesitancy to harvest free flaps in often-unfamiliar patient anatomy as well as difficulty in revascularization when necessary due to vessel caliber and inexperience from vascular surgery experts^[10,13]. However, this study shows that the free tissue transfer in this setting is well described with good outcomes and should be pursued.

Table 3. Major outcomes and follow-up

Author	Failure	Infection	Growth injury	RTOR	Follow-up
Elbataway et al. ^[15]	2	3	0	2	
Rinker et al. ^[12]	3	9	2	5	4.5 years
Lee et al. ^[13]	10	0	0	10	
Momeni et al. ^[14]	2	2	0	4	
Hu et al. ^[16]	0	0	0	0	14 months
Sui et al. ^[17]	0	0	0	2	
Khadim et al. ^[18]	1	0	0	1	

RTOR: Return to the operating room.

This study showed that most authors find excellent outcomes with flap success and when long-term studies are available, pediatric functional results are acceptable. Hesitancy in the pursuit of free flaps in this population stems in part from the earliest reports describing small vessel caliber, though subsequent reports and the development of the “super microsurgery” concept have helped mitigate these concerns^[8,22,23]. In fact, further research has shown that vessel caliber is not the limiting factor, but rather vessel mismatch - a more controllable variable that can be modified by trimming of the larger vessel or expansion of the smaller vessel may - be the root of complications^[10,24]. Regardless, the flap failure rate was lower than that which is documented in the adult population for lower extremity trauma reconstruction. This may be for several reasons - there is likely a higher acuity of patient selection in the pediatric cohort of whom to select to pursue free-tissue transfer. Further, pediatric trauma may likely be routed to specialized centers at an earlier time-frame as compared to adults, which can help further lend to an optimized wound bed as opposed to delaying care^[14,25]. Finally, the innate enhanced healing of children and general lack of comorbidities, such as diabetes, peripheral vascular disease, and smoking status, may also contribute to improved outcomes^[3,6-9,26]. Thus, in the appropriately selected patient, pediatric free tissue transfer appears to be a strong choice, and this study may suggest that more aggressive pursuit of this option may be indicated based on these results.

Salvage vs. Amputation

Ultimately, the decision to pursue free-flap reconstruction is complex. Prior studies in the adult population have attempted to describe algorithms for which patients should be salvaged vs. amputated. The famed 2002 Lower Extremity Assessment Project found that amputation is at least non-inferior to salvage^[4]. Further, numerous studies indicate that many expert trauma centers follow their own niche algorithms and clinical decision making, and that one specific tool has not yet been validated^[5,13,27,28]. Thus, this brings upon a necessary evaluation on a specific patient by patient specific-basis. The benefits of the pursuit of amputation are that immediate rehabilitation may soon be sought after. This includes the fitting of an appropriate prosthesis, which will be adjusted as growth commences, particularly if the child has not yet gone through puberty. Attempted salvage, while obviously appealing to many children and their families, may be fraught with complications, including additional revision surgery, extended hospital length of stay, and increased costs, which may ultimately commence in a secondary amputation, as shown in the adult population^[5,29]. However, the benefits of salvage are psychological, especially at a very young age, and although there is fear that attempted salvage may compromise growth and ultimately functional outcomes, the results of this study indicate that this is a relatively rare complication. Therefore, if free tissue transfer is possible, and if the patient is deemed an appropriate surgical candidate, then free tissue transfer should be highly considered, given strong outcomes and strong long-term functionality based on the available data [Table 4].

Logistical limitations to salvage

Despite the desire to pursue microvascular reconstruction by the microsurgeon, there are several other

Table 4. Algorithm to free flap harvest and selection

Factors to free flap harvest
Patient medically stabilized
Extensively exposed bone, tendon, or neurovasculature
Vascular and orthopedic fixation
Adequate wound debridement
Wound bed preparation and temporization with negative pressure wound therapy
Absence of local flap options
Efficient timing (Ideal under 10-30 days when possible)
Flap selection
-Perforator flap UNLESS
-Extensive, three-dimensional defect
-Inadequate donor site, tissue surface area, or donor site damage

factors that may hinder availability from achieving successful soft tissue transfer. In situations where extensive vascular injury is involved, or where prolonged ischemic time exists, there may be difficulty in achieving re-vascularization. Pediatric vascular surgery is not a standalone sub-specialty, and vascular surgeons may not have the experience with tiny vessels^[30,31]. In this case, the microsurgeon may take on the role of micro-anastomosis to pursue re-vascularization, though there may be unfamiliarity with these procedure types^[31]. Further concern over limited reports and surgeon experience with pediatric free tissue transfer to the lower extremity following trauma have impeded wider spread use. Timing of reconstruction, ideal flap type, and concerns over physiological vasospasm have introduced hesitancy in harvest^[7-9,11]. Despite the fact that the use of free tissue transfer has been reported upon successfully, some of these remain technically challenging cases. Vessel caliber and surgeon inexperience are limiting factors in applicability, as well as previously described poor surgical outcomes that are historical but nonetheless may perpetuate^[8,14,22,23]. Post-operatively, many centers do not have the expertise to care for pediatric free-flaps, and post-operative protocols, such as dangle protocols, are largely unexplored in the pediatric population compared to their adult counterparts^[32].

Flap selection

The selection of flap is an oft-debated topic in microsurgery, particularly in the setting of lower extremity trauma. Historically, the muscle-based flap was the dominant flap selected; however, in recent years, the fascial-based perforator flap has become an increasingly popular option^[33,34]. The advantages of the perforator flap are the ease of harvest, lower donor site morbidity, greater pliability for areas of thinner surrounding soft tissue, such as the ankle, and greater ease in re-elevation if necessary, which may often be the case when there is extensive bony damage requiring orthopedic hardware and orthopedic revision^[9,35]. Donor site morbidity, in particular, is a critical discussion point in the pediatric patient, as muscle sacrifice can have adverse effects on growth, functional, and aesthetic outcomes, thus lending an additional important consideration for utilizing perforator flaps. The muscle base flap was once preferred due to its bulky nature, which afforded the ability to contour dead space and complex three-dimensional defects. Prior research also indicated that the muscle base flap provided a strong blood supply that was beneficial in aiding the eradication of bacterial infection. However, this comes with the caveat of increased donor site morbidity, and a decreased cosmetic outcome that may require subsequent de-bulking procedures^[9,14,33,35,36]. The psychological adversity afforded by worsened cosmesis should especially be highlighted in children, as this may have adverse effects on their mental and social growth. More recent research from several high-volume trauma centers has indicated that perforator flaps and muscle flaps likely have similar outcomes, and thus it appears that perforator flaps are gaining popularity and that each defect must be evaluated on a patient-by-patient basis.

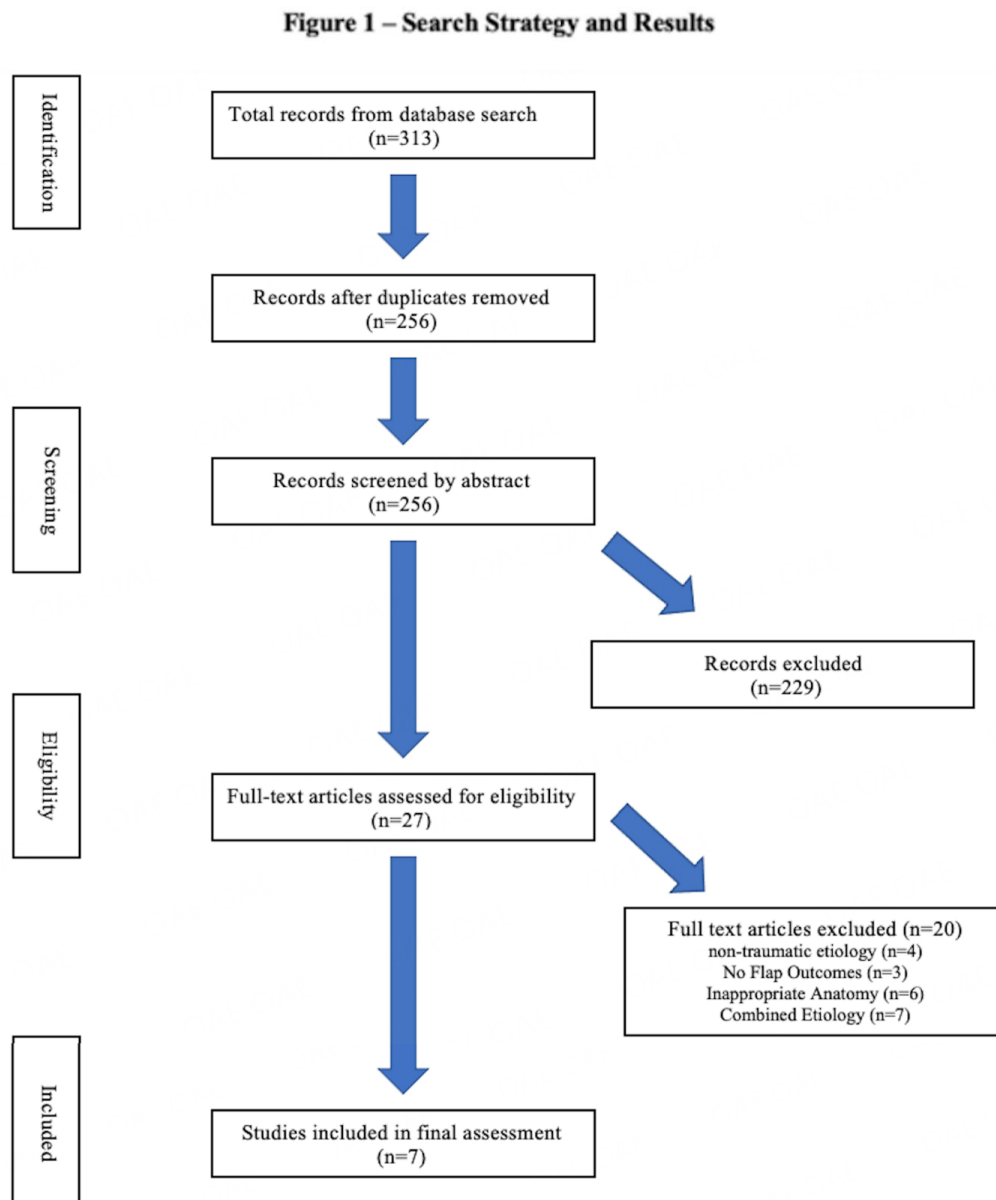


Figure 1. Search strategy, results, and screening.

Vessel selection

Even when the appropriate flap is selected, there is a question regarding the selection of the appropriate recipient vessel. In this study, the anterior tibial and posterior tibial arteries were the most commonly chosen. The choice of selection will in part be dictated by vessel injury, anatomy of the defect, and zone of injury^[37,38]. The posterior tibial vascular bundle is likely to be “safer” from injury given its deep course, and may be suitable as a rescue vessel even when not anatomically favorable; however, some have argued that anastomosis to injured vessels may still be pursued^[38,39]. However, in specific regard to the posterior tibial

artery, damage to this vessel has been shown to be prognostic of worsened flap outcomes, including failure, takebacks, and major complications, and may potentially serve as a surrogate for the extent of trauma and micro-inflammatory milieu^[27,37,38,40].

Limitations

There are several limitations to this study, given the study design. Many studies describing lower extremity reconstruction combine oncologic and traumatic etiology; however, given the associated zone of injury, vessel manipulation, and complex patient status of trauma patients, these could not be combined, causing a significant loss of sample size and limiting the number of studies for inclusion. There is likely a component of selection bias with patients, and increasing liberal use of free flaps in this population may render worsened outcomes. Due to the desire to capture studies with moderate patient sample sizes in order to discern trends, some smaller case series were also not included. Additionally, the exact timing of reconstruction was not immediately discerned though most reconstruction occurred within 7-10 days, and this has previously been shown to have positive effects on flap outcomes, representing an upgrade in the original Godina paradigm likely due to advanced local wound care and vacuum assisted closure therapy^[27,39]. Finally, despite this, most studies are extremely small and heterogenous, rendering absolute conclusions difficult, though the early reports indicate strong success.

In conclusion, free tissue transfer for pediatric lower extremity trauma is an important tool that likely leads to powerful outcomes. This study shows that based on existing data, free flap utilization for pediatric patients is an adequate modality for repair, and may warrant greater consideration moving forward.

DECLARATIONS

Authors' contributions

Made substantial contributions to conception and design of the study and performed data analysis, acquisition, writing, and interpretation: Othman S, Knobel D

Provided administrative, technical, and material support: Knobel D

Availability of data and materials

Not applicable.

Financial support and sponsorship

None.

Conflicts of interest

All authors declare that there are no relevant conflicts of interest.

Ethical approval and consent to participate

Not applicable.

Consent for publication

Not applicable.

Copyright

© The Author(s) 2022.

REFERENCES

1. Read KM, Burgess AR, Dischinger PC, et al. Psychosocial and physical factors associated with lower extremity injury. *Annu Proc Assoc Adv Automot Med* 2002;46:289-303. [PubMed](#)
2. Butowicz CM, Dearth CL, Hendershot BD. Impact of traumatic lower extremity injuries beyond acute care: movement-based considerations for resultant longer term secondary health conditions. *Adv Wound Care (New Rochelle)* 2017;6:269-78. [DOI](#) [PubMed](#) [PMC](#)
3. Upton J, Guo L. Pediatric free tissue transfer: a 29-year experience with 433 transfers. *Plast Reconstr Surg* 2008;121:1725-37. [DOI](#) [PubMed](#)
4. Bosse MJ, MacKenzie EJ, Kellam JF, et al. An analysis of outcomes of reconstruction or amputation after leg-threatening injuries. *N Engl J Med* 2002;347:1924-31. [DOI](#) [PubMed](#)
5. Busse JW, Jacobs CL, Swiontkowski MF, Bosse MJ, Bhandari M; Evidence-Based Orthopaedic Trauma Working Group. Complex limb salvage or early amputation for severe lower-limb injury: a meta-analysis of observational studies. *J Orthop Trauma* 2007;21:70-6. [DOI](#) [PubMed](#)
6. Shenaq SM, Dinh TA. Pediatric microsurgery. Reconstruction by free tissue transfer. *Clin Plast Surg* 1990;17(1):85-94. [PubMed](#)
7. Clarke HM, Upton J, Zuker RM, Manktelow RT. Pediatric free tissue transfer: an evaluation of 99 cases. *Can J Surg* 1993;36(6):525-28. [PubMed](#)
8. Serletti JM, Schingo VA Jr, Deuber MA, Carras AJ, Herrera HR, Reale VF. Free tissue transfer in pediatric patients. *Ann Plast Surg* 1996;36:561-8. [DOI](#) [PubMed](#)
9. Upton J, Guo L, Labow BI. Pediatric free-tissue transfer. *Plast Reconstr Surg* 2009;124:e313-26. [DOI](#) [PubMed](#)
10. Devaraj V, Kay S, Batchelor A, Yates A. Microvascular surgery in children. *British Journal of Plastic Surgery* 1991;44:276-80. [DOI](#) [PubMed](#)
11. Canales F, Lineaweaver W, Furnas H, et al. Microvascular tissue transfer in paediatric patients: analysis of 106 cases. *British Journal of Plastic Surgery* 1991;44:423-7. [DOI](#) [PubMed](#)
12. Rinker B, Valerio IL, Stewart DH, Pu LL, Vasconez HC. Microvascular free flap reconstruction in pediatric lower extremity trauma: a 10-year review. *Plast Reconstr Surg* 2005;115:1618-24. [DOI](#) [PubMed](#)
13. Lee ZH, Daar DA, Stranix JT, et al. Risk factors for microvascular free flaps in pediatric lower extremity trauma. *Microsurgery* 2020;40:44-50. [DOI](#) [PubMed](#)
14. Momeni A, Lanni M, Levin LS, Kovach SJ. Microsurgical reconstruction of traumatic lower extremity defects in the pediatric population. *Plast Reconstr Surg* 2017;139:998-1004. [DOI](#) [PubMed](#)
15. Elbatawy A, Elgammal M, Zayid T, et al. Pediatric microsurgery in the reconstruction of complex posttraumatic foot and ankle defects: a long-term follow-up with a comprehensive review of the literature. *J Reconstr Microsurg* 2021;37:193-200. [DOI](#) [PubMed](#)
16. Hu R, Ren YJ, Yan L, et al. A free anterolateral thigh flap and iliotibial band for reconstruction of soft tissue defects at children's feet and ankles. *Injury* 2015;46:2019-23. [DOI](#) [PubMed](#)
17. Sui X, Cao Z, Pang X, et al. Reconstruction of moderate-sized soft tissue defects in foot and ankle in children: Free deep inferior epigastric artery perforator flap versus circumflex scapular artery perforator flap. *J Plast Reconstr Aesthet Surg* 2019;72:1494-502. [DOI](#) [PubMed](#)
18. Khadim MF, Emam A, Wright TC, Chapman TWL, Khan U. A comparison between the major trauma centre management of complex open lower limb fractures in children and the elderly. *Injury* 2019;50:1376-81. [DOI](#) [PubMed](#)
19. Klifto KM, Azoury SC, Othman S, Klifto CS, Levin LS, Kovach SJ. The value of an orthoplastic approach to management of lower extremity trauma: systematic review and meta-analysis. *Plast Reconstr Surg Glob Open* 2021;9:e3494. [DOI](#) [PubMed](#) [PMC](#)
20. Argamaso RV, Lewin ML, Baird AD, Rothfleisch S. Cross-leg flaps in children. *Plast Reconstr Surg* 1973;51:662-6. [DOI](#) [PubMed](#)
21. Kapadia A, Cheruvu VR, John JR, Tripathy S, Sharma RK. Reconstruction in pediatric orthopedic trauma: the role of primary cross leg flap cover. *J Pediatr Orthop B* 2017;26:172-8. [DOI](#) [PubMed](#)
22. Ohmori K, Harii K, Sekiguchi J, Torii S. The youngest free groin flap yet? *British Journal of Plastic Surgery* 1977;30:273-6. [DOI](#) [PubMed](#)
23. Duteille F, Lim A, Dautel G. Free flap coverage of upper and lower limb tissue defects in children: a series of 22 patients. *Ann Plast Surg* 2003;50:344-9. [DOI](#) [PubMed](#)
24. Rickard RF, Engelbrecht GH, Hudson DA. Experimental investigation of two techniques of arterial microanastomosis used to manage a small-to-large diameter discrepancy. *J Plast Reconstr Aesthet Surg* 2011;64:1088-95. [DOI](#) [PubMed](#)
25. Klifto KM, Azoury SC, Othman S, Klifto CS, Levin LS, Kovach SJ. Direct admission versus transfer to a tertiary hospital for definitive management of lower extremity injuries: Systematic review and meta-analysis. *J Trauma Acute Care Surg* 2021;90:756-65. [DOI](#) [PubMed](#)
26. Srikanth R. Free tissue transfer in pediatric lower limb trauma. *Indian J Plast Surg* 2019;52:37-44. [DOI](#) [PubMed](#) [PMC](#)
27. Othman S, Stranix JT, Piwnica-Worms W, et al. Microvascular free tissue transfer for reconstruction of complex lower extremity trauma: predictors of complications and flap failure. *Microsurgery* 2021. [DOI](#) [PubMed](#)
28. Azoury SC, Stranix JT, Othman S, et al. Outcomes following soft-tissue reconstruction for traumatic lower extremity defects at an orthoplastic limb salvage center: The need for Lower Extremity Guidelines for Salvage (L.E.G.S.). *Orthoplastic Surgery* 2021;3:1-7. [DOI](#)
29. Piwnica-Worms W, Stranix JT, Othman S, et al. Risk factors for lower extremity amputation following attempted free flap limb salvage. *J Reconstr Microsurg* 2020;36:528-33. [DOI](#) [PubMed](#)

30. Bonasso PC, Dassinger MS, Smeds MR, Moursi MM. Pediatric vascular surgical practice patterns. *Ann Vasc Surg* 2019;54:103-9.e8. [DOI](#) [PubMed](#)
31. Gans I, Baldwin KD, Levin LS, et al. A Lower extremity musculoskeletal and vascular trauma protocol in a children's hospital may improve treatment response times and appropriate microvascular coverage. *J Orthop Trauma* 2015;29:239-44. [DOI](#) [PubMed](#)
32. Lee ZH, Ramly EP, Alfonso AR, et al. Dangle protocols in lower extremity reconstruction. *J Surg Res* 2021;266:77-87. [DOI](#) [PubMed](#)
33. Khouri RK, Shaw WW. Reconstruction of the lower extremity with microvascular free flaps: a 10-year experience with 304 consecutive cases. *J Trauma* 1989;29:1086-94. [DOI](#) [PubMed](#)
34. Sofiadellis F, Liu DS, Webb A, Macgill K, Rozen WM, Ashton MW. Fasciocutaneous free flaps are more reliable than muscle free flaps in lower limb trauma reconstruction: experience in a single trauma center. *J Reconstr Microsurg* 2012;28:333-40. [DOI](#) [PubMed](#)
35. Cho EH, Shammam RL, Carney MJ, et al. Muscle versus fasciocutaneous free flaps in lower extremity traumatic reconstruction: a multicenter outcomes analysis. *Plast Reconstr Surg* 2018;141:191-9. [DOI](#) [PubMed](#)
36. Boyd LC, Bond GA, Hamidian Jahromi A, Kozusko SD, Kokkalis Z, Konofaos P. Microvascular reconstruction of pediatric lower extremity trauma using free tissue transfer. *Eur J Orthop Surg Traumatol* 2019;29:285-93. [DOI](#) [PubMed](#)
37. Chen HC, Chuang CC, Chen S, Hsu WM, Wei FC. Selection of recipient vessels for free flaps to the distal leg and foot following trauma. *Microsurgery* 1994;15:358-63. [DOI](#) [PubMed](#)
38. Stranix JT, Lee ZH, Jacoby A, et al. Not all gustilo type IIIB fractures are created equal: arterial injury impacts limb salvage outcomes. *Plast Reconstr Surg* 2017;140:1033-41. [DOI](#) [PubMed](#)
39. Lee ZH, Stranix JT, Rifkin WJ, et al. Timing of microsurgical reconstruction in lower extremity trauma: an update of the godina paradigm. *Plast Reconstr Surg* 2019;144:759-67. [DOI](#) [PubMed](#)
40. Haddock NT, Weichman KE, Reformat DD, Kligman BE, Levine JP, Saadeh PB. Lower extremity arterial injury patterns and reconstructive outcomes in patients with severe lower extremity trauma: a 26-year review. *J Am Coll Surg* 2010;210:66-72. [DOI](#) [PubMed](#)