

Case Report

Osteonecrosis of the jaw in a patient with acute myeloid leukemia, who received azacitidine

Ourania Nicolatou-Galitis¹, Dimitra Galiti², Maria Moschogianni³, Sotirios Sachanas³, Beatrice J. Edwards⁴, Cesar A. Migliorati⁵, Gerassimos Pangalis⁶

¹Clinic of Hospital Dentistry, Dental Oncology Unit, Dental School, National and Kapodistrian University of Athens, 15451 Athens, Greece.

²Clinic of Oral Diagnosis and Radiology, Dental School, National and Kapodistrian University of Athens, 15451 Athens, Greece.

³Department of Hematology, Athens Medical Center-Psychikon Branch, 15451 Athens, Greece.

⁴Geriatric Medicine, Department of General Internal Medicine, Center for Research and Education, University of Texas, MD Anderson Cancer Center, Houston, TX 77042, USA.

⁵Department of Diagnostic Sciences and Oral Medicine, University of Tennessee Health Science Center College of Dentistry, Memphis, TX 37174, USA.

⁶Department of Hematology, Athens Medical Center-Psychikon Branch, 15451 Athens, Greece.

Correspondence to: Prof. Ourania Nicolatou-Galitis, Clinic of Hospital Dentistry, Dental Oncology Unit, Dental School, National and Kapodistrian University of Athens, Bouboulinas 41, N. Psyhico, 15451 Athens, Greece. E-mail: nicolatou.galitis@hotmail.com



Ourania Nicolatou-Galitis is Professor and Chair of the Dental Oncology, at the National and Kapodistrian University of Athens, Greece. She is President of the International Society of Oral Oncology and serves as Chair of the Bone Study Group, MASCC.org. Osteonecrosis of the jaw in medication is her major research interest.

ABSTRACT

The first case of osteonecrosis of the jaw (ONJ) related to azacitidine therapy was reported. A 64-year-old male with acute myeloid leukemia, who received 5-azacitidine, presented with pain and purulence of the right second premolar. An unsuccessful endodontic therapy resulted in dental extraction 6 months later. The post-extraction non-healing socket was managed with antibiotics and multiple surgical debridements without response. ONJ stage 2 was diagnosed 12 months after the initial symptoms of pain and purulence and was managed conservatively. Currently the patient is still receiving 5-azacitidine therapy, while ONJ remains asymptomatic. This case highlights the presence of alveolar bone disease prior to the appearance of ONJ. Osteonecrosis in chemotherapy, although rare, may increase as long-term survival of cancer patients, who receive those medications increases. Health care professionals need to be alert, while collaboration with an experienced oral/dental oncologist would be beneficial to the patient.

Key words: Acute myeloid leukemia; azacitidine; periodontal/dental disease and infection; dental extraction; osteonecrosis of the jaw

INTRODUCTION

Osteonecrosis of the jaw (ONJ) in cancer patients is related to antiresorptive therapy, such as bisphosphonates and denosumab, and angiogenesis inhibitors, such as bevacizumab and sunitinib.^[1-3] Medications with antiangiogenic effect, such as sorafenib, imatinib, everolimus, aflibercept, trastuzumab and pazopanib were related to ONJ in few case reports.^[4-8] Ipilimumab, a monoclonal antibody against cytotoxic T-Lymphocyte-Associated Antigen-4 (CTLA-4)

was recently associated with ONJ.^[9] In patients receiving antiresorptives, concurrent chemotherapy was reported as a risk factor, while chemotherapy alone has also been related to ONJ in three patients.^[10-12]

Dental extraction has been considered as one of the causes for ONJ.^[13-15] This myth has, however, been questioned.^[16] It is now believed that the dental extraction, indicated due

This is an open access article distributed under the terms of the Creative Commons Attribution-NonCommercial-ShareAlike 3.0 License, which allows others to remix, tweak, and build upon the work non-commercially, as long as the author is credited and the new creations are licensed under the identical terms.

For reprints contact: service@oaepublish.com

How to cite this article: Nicolatou-Galitis O, Galiti D, Moschogianni M, Sachanas S, Edwards BJ, Migliorati CA, Pangalis G. Osteonecrosis of the jaw in a patient with acute myeloid leukemia, who received azacitidine. J Cancer Metasta Treat 2016;2:220-3.

Received: 31-01-2016; **Accepted:** 10-05-2016.

Access this article online

Quick Response Code:



Website:

<http://www.jcmtjournal.com>

DOI:

10.20517/2394-4722.2016.06

to periodontal/dental infection and disease, will lead to exposure of the alveolar bone, which may already be necrotic and will not heal.^[17] Infection, within a unifying concept of medication-related impaired immune response was proposed to play an important role in the pathophysiology of ONJ.^[18]

In this paper we report what we believe is the first case of ONJ in a patient with acute myeloid leukemia (AML), who was treated with azacitidine. The presence of alveolar bone disease leads to the dental extraction and the subsequent diagnosis of ONJ.

CASE REPORT

A 64-year-old male, smoker was diagnosed on April 2010 with myelodysplastic syndrome (refractory anemia) of low-risk according to IPSS (normal karyotype, without cytopenia, blasts 3-4%).^[19] One year later the patient progressed to refractory anemia with excess blasts, type II (RAEB-II), normal karyotype, without cytopenia, blasts 15%.^[20] He was placed on 5-azacitidine therapy [75 mg/m² (150 mg) day 1 to day 7 on 28 days cycle] with partial remission (Hgb > 11 g/dL, Platelets > 100 × 10⁹/L, Neutrophils > 1.0 × 10⁹/L, bone marrow blasts decreased by 50% but still > 5%). Two years later, after 17 cycles of 5-azacitidine, he progressed to AML. His complete blood counts showed: Hemoglobin 9.6 gr/dL, white blood cells 21.6 × 10⁹/L, absolute neutrophil count of 4.0 × 10⁹/L, immature white blood cells (myelocytes, metamyelocytes) and blasts 5.0 × 10⁹/L, platelets 142.0 × 10⁹/L. Bone marrow biopsy revealed 25-30% infiltration of CD34 (+) cells (blasts). Cytogenetic analysis (karyotype) was normal (46XY). He received 7 + 3 induction chemotherapy [intravenous infusion of Cytarabine (200 mg/m² day 1 through day 7) and Idarubicin 10 mg/m² on 30' infusion on day 2, 4, 6]. During hospitalization the patient developed neutropenic fever, managed with empiric antibiotic treatment (piperacilin + tazobactam and amikacin) and red

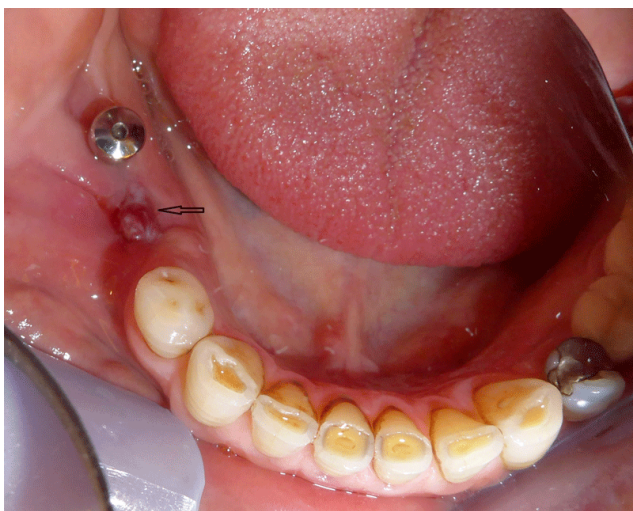

Figure 1: Swelling, fistula and purulence on the post extraction non-healing socket (July 2015). Necrotic bone could be probed through the fistula

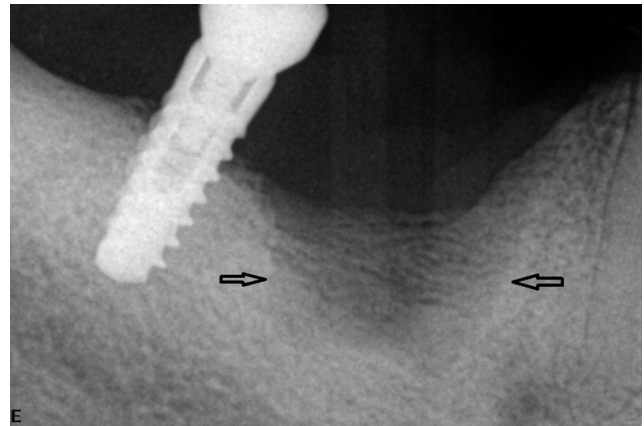


Figure 2: Radiolucency is seen in the socket (July 2015)

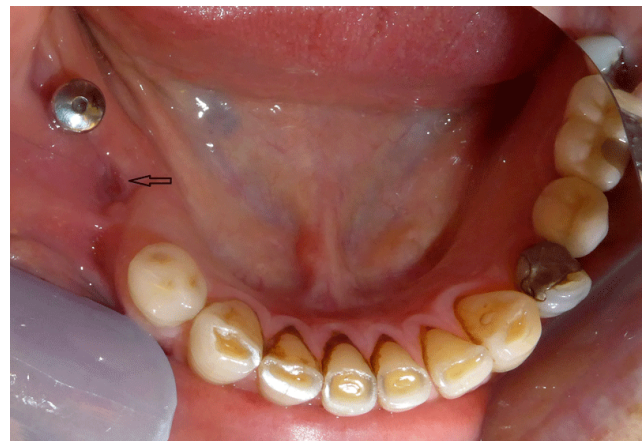

Figure 3: Remission of pain, swelling and purulence (August 2015)

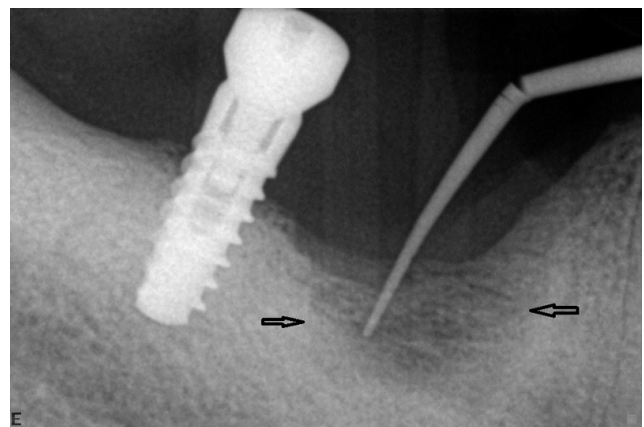


Figure 4: Radiolucency remains in the bone, socket area (September 2015). A gutta-percha cone has been inserted through the fistula

blood cell and platelets transfusions. Two months later, bone marrow aspiration and flow cytometry disclosed persistent disease.

Patient did not consent to receive induction chemotherapy and was placed on low intensity chemotherapy with hydroxyurea per os for six months. Bone marrow biopsy revealed greater than 60% blast cell infiltration, with a normal karyotype and patient was treated again with 5-azacitidine from that time to present. Bone marrow blasts dropped to 14%.

On June 2014 the patient received a restoration of the 2nd right mandibular premolar because of pain. Pain and purulence persisted in spite of endodontic therapy. Dental extraction was recommended and completed in December 2014. The post-extraction follow up revealed a non-healing socket. This area was managed with antibiotics (amoxicillin alone or combined with metronidazole) and surgical debridements (January to July 2015). A biopsy taken from the soft tissue of the socket showed granulation tissue. On July 2015 pain, swelling and purulence at the site of previous extraction [Figure 1], with necrotic bone being probed through a fistula and radiolucency, was observed on the periapical X-ray [Figure 2], leading to the diagnosis of osteonecrosis.

Management with antibiotics, ozone oil applications and low level laser therapy (LLLT) treatments [Ripamonti-11, Nicolatou-13], twice weekly, resulted in remission of symptoms [Figure 3], while the radiolucency and fistula persisted [Figure 4]. This is a retrospective case presentation from existing de-identified medical record data. Patient gave consent for the medical record review.

DISCUSSION

Azacitidine is a chemical analogue of the cytosine nucleoside and functions as a DNA demethylating agent and as an antimetabolite.^[21] Reduced cell division and growth may result from demethylation of DNA. Azacitidine, as a metabolite, can exert a direct myelotoxic and cytotoxic effect. Azacitidine, by both its demethylating and antimetabolite actions, might have negatively affected the increased need of cellular division and growth of bone remodeling and the soft tissue healing after the dental extraction in our patient. Azacitidine-related cytotoxicity and impaired immune response to infection could have also contributed to the development of alveolar bone disease and infection, which had preceded the appearance of ONJ.

Gemcitabine chemotherapy was associated with ONJ in a patient to Sezary syndrome, an aggressive leukemic form of cutaneous T-cell lymphoma.^[12] In that case, ONJ was related to the effects of gemcitabine, through suppression of vascular endothelial growth factor. Osteonecrosis was also reported in a patient with AML and in one with breast cancer, who received aggressive chemotherapy. No azacitidine was administered to the above patient with AML. Neutropenia and severe immune suppression were related to the development of ONJ in those cases.^[10] The presently reported patient developed ONJ while he was on azacitidine therapy. T-cell-related altered immune response and infection were related with ONJ in another patient, with advanced metastatic melanoma, who received ipilimumab.^[9] Pain, purulence and periodontal ligament widening indicating alveolar bone disease and infection preceded the appearance of ONJ in all those cases, including the present case. Our findings support the proposed role of

alveolar bone disease and infection in the pathogenesis of ONJ.^[17,18]

The major treatment objectives for patients with ONJ are pain and infection control and minimization of ONJ progression. Antibiotics and topical antiseptics combined with ozone oil applications and LLLT are used as best available clinical practice for early ONJ stages.^[1,5,17,22] Ozone oil has antimicrobial and healing properties, while LLLT biostimulation can improve healing.^[23,24] The patient was managed with antibiotics, amoxicillin and/or metronidazole, ozone oil applications and LLLT. The long delay (12 months) for the diagnosis of ONJ and the multiple unsuccessful dental and surgical interventions, combined with the continued azacitidine therapy, may be related to the persistent ONJ lesion.

In conclusion, this case increased the list of medications that can lead to ONJ and highlighted the importance of the presence of localized alveolar bone infection prior to the appearance of ONJ. The occurrence, though rare, of this potentially serious complication may increase with the long-term survival of cancer patients.

Financial support and sponsorship

Nil.

Conflicts of interest

There are no conflicts of interest.

REFERENCES

1. Ruggiero SL, Dodson TB, Fantasia J, Goodday R, Aghaloo T, Mehrotra B, O’Ryan F. Medication-related osteonecrosis of the jaw- 2014 update. 2014;1-26. Available from: http://www.aaoms.org/docs/position_papers/mronj_position_paper.pdf.
2. Greuter S, Schmid F, Ruhstaller T, Thuerlimann B. Bevacizumab-associated osteonecrosis of the jaw. *Ann Oncol* 2008;19:2091-2.
3. Nicolatou-Galitis O, Migkou M, Psyrri A, Bamias A, Pectasides D, Economopoulos T, Raber-Durlacher JE, Dimitriadis G, Dimopoulos MA. Gingival bleeding and jaw bone necrosis in patients with metastatic renal cell carcinoma receiving sunitinib: report of 2 cases with clinical implications. *Oral Surg Oral Med Oral Pathol Oral Radiol* 2012;113:234-8.
4. Kim DW, Jung YS, Park HS, Jung HD. Osteonecrosis of the jaw related to everolimus: a case report. *Br J Oral Maxillofacial Surg* 2013;5:e302-4.
5. Nicolatou-Galitis O, Razis E, Galiti D, Vardas E, Tzerbos F, Labropoulos S. Osteonecrosis of the jaw in a patient with chronic myelogenous leukemia receiving imatinib - a case report with clinical implications. *Forum Clin Oncol* 2013;4:29-33.
6. Ponzetti A, Pinta F, Spadi R, Mecca C, Fanchini L, Zanini M, Ciuffreda L, Racca P. Jaw osteonecrosis associated with aflibercept, irinotecan and fluorouracil: attention to oral district. *Tumori* 2015 Sep 1:0. doi: 10.5301/tj.5000405.
7. Pilanci KN, Alco G, Ordu C, Sarsenov D, Celebi F, Erdogan Z, Agacayak F, Ilgun S, Tecimer C, Demir G, Eralp Y, Okkan S, Ozmen V. Is administration of trastuzumab an independent risk factor for developing osteonecrosis of the jaw among metastatic breast cancer patients under zoledronic acid treatment? *Medicine* 2015;94:e671.
8. Papadopoulou E, Nicolatou-Galitis O, Vardas E, Repoussis P,

- Ardavanis A, Bafaloukos D, Sgouros J, Christodoulou C, Vaslamatzis M, Linardou H, Ntalakou E, Marioli N, Stefanou D, Syrigos K. Treatment and prevention of osteonecrosis of the jaw associated with medication: 2009-2014. *Support Care Cancer* 2015;23:S1-388.
9. Owosho AA, Scordo M, Yom SK, Randazzo J, Chapman PB, Hurn JM, Estilo CL. Osteonecrosis of the jaw a new complication related to Ipilimumab. *Oral Oncol* 2015;51:e100-1.
 10. Infante-Cossio P, Lopez-Martin JC, Gonzalez-Cardero E, Martinez-de-Fuentes R, Casas-Fernandez-Tejerina A. Osteonecrosis of the maxilla associated with cancer chemotherapy in patients wearing dentures. *J Oral Maxillofac Surg* 2012;70:1587-92.
 11. Gaudin E, Seidel L, Bacevic M, Rompen E, Lambert F. Occurrence and risk indicators of medication-related osteonecrosis of the jaw after dental extraction: a systematic review and meta-analysis. *J Clin Periodontol* 2015;42:922-32.
 12. DeSesa CR, Appugounder S, Haberland C, Johnson MP. Osteonecrosis of the jaw in association with chemotherapy in the setting of cutaneous T-cell lymphoma. *J Oral Maxillofac Surg* 2016;74:292-301.
 13. Nicolatou-Galitis O, Papadopoulou E, Sarri T, Boziari P, Karayanni A, Kyrtsionis MC, Repousis P, Barbounis V, Migliorati CA. Osteonecrosis of the jaw in oncology patients treated with bisphosphonates: prospective experience of a dental oncology center. *Oral Surg Oral Med Oral Pathol Oral Radiol Endod* 2011;112:195-202.
 14. Vardas E, Coward T, Papadopoulou E, Nicolatou-Galitis O. Dental extractions as the major local risk factor of bisphosphonates related jaw osteonecrosis in cancer patients receiving intravenous bisphosphonates therapy. A systematic review. *Mediterr Oncol J MOJ* 2014;1:26-33.
 15. Yazdi PM, Schiodt M. Dentoalveolar trauma and minor trauma as precipitating factors for medication-related osteonecrosis of the jaw (ONJ): a retrospective study of 149 consecutive patients from the Copenhagen ONJ Cohort. *Oral Surg Oral Med Oral Pathol Oral Radiol* 2015;119:416-22.
 16. Migliorati CA. Dispelling the myths associated with osteonecrosis of the jaw. *ASCO Post* 2015;6:Issue 15.
 17. Nicolatou-Galitis O, Razis E, Galiti D, Galitis E, Labropoulos S, Tsimpidakis A, Sgouros J, Karampeazis A, Migliorati C. Periodontal disease preceding osteonecrosis of the jaw (ONJ) in cancer patients receiving antiresorptives alone or combined with targeted therapies: report of 5 cases and literature review. *Oral Surg Oral Med Oral Pathol Oral Radiol* 2015;120:699-706.
 18. Katsarelis H, Shah NP, Dhariwal DK, Pazianas M. Infection and medication-related osteonecrosis of the jaw. *J Dent Res* 2015;94:534-9.
 19. Greenberg P, Cox C, LeBeau MM, Fenaux P, Morel P, Sanz G, Sanz M, Vallespi T, Hamblin T, Oscier D, Ohyashiki K, Toyama K, Aul C, Mufti G, Bennett J. International scoring system for evaluating prognosis in myelodysplastic syndromes. *Blood* 1997;89:2079-88.
 20. Swerdlow SH, Campo E, Harris NL, Jaffe ES, Pileri SA, Stein H, Thiele J, Vardiman JW. WHO Classification of Tumours of Haematopoietic and Lymphoid Tissues. Lyon, France: IARC; 2008;87-107.
 21. <http://chemocare.com/chemotherapy/drug-info/Vidaza.aspx>. Downloaded: January 2, 2016.
 22. Ripamonti C, Cislighi E, Mariani L, Maniezzo M. Efficacy and safety of medical ozone (O₃) delivered in oil suspension applications for the treatment of osteonecrosis of the jaw in patients with bone metastases treated with bisphosphonates: Preliminary results of a phase I-II study. *Oral Oncol* 2011;47:185-90.
 23. Vesconi P, Giovannacci I, Merigo E, Meleti M, Manfredi M, Formaini C, Namour S. Tooth extractions in high-risk patients under bisphosphonate therapy and previously affected with osteonecrosis of the jaws: surgical protocol supported by low-level Laser therapy. *J Craniofac Surg* 2015;26:696-9.
 24. Basso FG, Turroni APS, Soares DG, Hebling J, de Souza Costa CA. Low-level laser therapy for osteonecrosis lesions: affects on osteoblasts treated with zoledronic acid. *Support Care Cancer* 2014;22:2741-8.